

EDUCATION AFTER HEMISPHERECTOMY

An Introductory Guide For The Educational Team



The Brain Recovery Project

BELIEVE IN THE OTHER HALF

TABLE OF CONTENTS

INTRODUCTION01

What is a hemispherectomy?
Functional, motor, and behavioral outcomes

EVALUATION PLANS AND ASSESSMENTS.....02

VISION03

Homonymous hemianopsia
Homonymous hemianopsia and reading challenges
Hemispatial neglect and vision
Visual processing
Other visual challenges

MOBILITY05

Hemiparesis
Coordination
Hemispatial neglect
Spasticity and tightness
Hip and shoulder subluxation

FINE MOTOR06

Hemiparesis
Hand/eye coordination

SENSORY06

HEARING07

Central auditory processing disorder
Hyperacusis
Misophonia

LEARNING AND INTELLECTUAL DISABILITIES.....08

Reading challenges
Phonics
Comprehension
Reading aloud
Nonverbal learning disorder
Organizational skills

SPEECH AND LANGUAGE10

Expressive verbal speech
Apraxia
Articulation and prosody

ASSISTIVE COMMUNICATION DEVICES11

BEHAVIOR11

Socialization
Sensory processing disorder
Behaviors and anti-epileptic medications

EMOTIONAL CHALLENGES12

Trauma and post-traumatic stress disorder
Social isolation

OTHER CONSIDERATIONS13

Headaches and migraines
Fatigue
Seizures
Hydrocephalus

The purpose of this guide is to provide educators with a broad overview of some of the challenges faced by a child after hemispherectomy surgery, as well as to provide parents and educators with some guidelines and strategies for intervention. It is not intended to be a comprehensive guide to all issues that may impact a child in the educational environment after hemispherectomy, nor is intended to be a predictor of outcomes in any way. Although each child is different, there are some commonalities after the procedure which are addressed here as they may have a profound impact on the child's success in the educational environment. Nothing in this guide should be interpreted as constituting legal or medical advice.

Unless otherwise indicated, "child" or "children" refers to a child who has had hemispherectomy surgery.

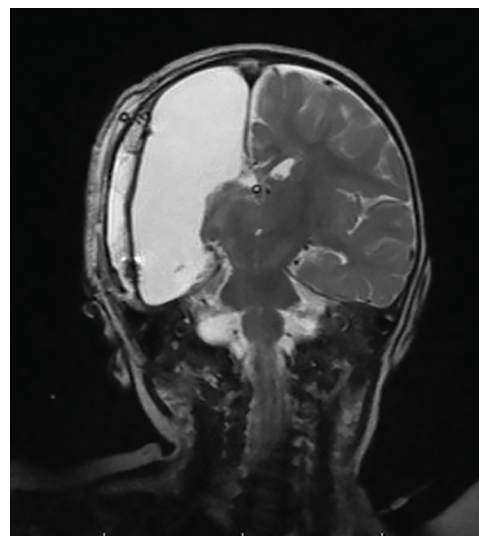


INTRODUCTION

What is a hemispherectomy?

A hemispherectomy is a surgical procedure where one half of the brain is removed or disabled in a final attempt to stop catastrophic childhood epilepsy that is unresponsive to anti-epileptic drugs. Although it is a drastic procedure, in most cases the quality of life for the child greatly improves afterwards. Some children have the procedure done in infancy, while others may develop like their typical peers for several years until their seizures begin and surgery is necessary.

The term hemispherectomy is used to describe many different surgical procedures that are used to completely disable and/or disconnect one side of the brain. In all hemispherectomy surgeries, the neurosurgeon's goal is to completely sever the corpus callosum so that the two sides of the brain cannot communicate information. Additionally, the four lobes of the affected hemisphere are either removed in their entirety or partially removed and disconnected from one another as well as from other important brain structures.



Functional, motor, and behavioral outcomes

Approximately 50-85 percent of children who have this procedure are seizure-free afterwards; however, the procedure leaves the child with severe physical and sensory deficits that are unavoidable. This includes the loss of half the child's field of vision (homonymous hemianopsia) and significant weakness (hemiparesis) on the opposite side of the body. Despite these challenges, a recent comprehensive study of over 100 children and adults who had childhood hemispherectomy reports that:

- **83%** are able to walk independently;
- **70%** have satisfactory speaking skills;
- **60%** participate in mainstream schools with assistance;
- **42%** over the age of 6 have satisfactory reading skills; and,
- **21%** of adults who had the procedure are gainfully employed.

EVALUATION PLANS AND ASSESSMENTS

Children after hemispherectomy are neurologically complicated. For this reason, a comprehensive evaluation plan - sometimes annually - is required to fully understand the impact the procedure has on the child throughout their educational experience.

A comprehensive evaluation plan should include the following assessments:

- health
- vision, including assessment for acuity, field loss, and cortical vision impairment;
- hearing, including assessment for central auditory processing;
- social and emotional status, including functional behavior assessment and psychological evaluation;
- general intelligence (where age appropriate);
- academic performance;
- communicative status, including augmentative communication and assistive technology; and,
- mobility/gross motor.

Because of the nature of hemispherectomy surgery, children are always at risk of new or recurring medical problems, new or changing learning disabilities, and social and emotional issues even many years after the procedure. As their bodies change and their minds develop, new physical, psychological and neurological issues may arise. They may develop more, not fewer, challenges in school. Any changes in their skills, capabilities, and emotional makeup must therefore be assessed in light of the procedure and related issues (such as return of seizures, onset of hydrocephalus, etc.)


VISION

Homonymous hemianopsia


Homonymous hemianopsia is a loss of half the visual field on the same side in both eyes. After hemispherectomy surgery, the child loses half of their field of vision directly opposite the side of the removed hemisphere.



View of a classroom for someone with normal vision



View of a classroom for someone with right homonymous hemianopsia after left hemispherectomy



View of a classroom for someone with left homonymous hemianopsia after right hemispherectomy

In a classroom setting, the child may be unable to see the teacher in the front or the classroom or the lesson plan on the wall. Seating location is important to ensure that the instructor is not in the child's field cut.

Homonymous hemianopsia can dramatically affect the child's ability to navigate the environment. They may bump into walls often, trip on objects on the floor, or be startled when something appears in their field of vision. Fear of falling or inability to navigate obstacles with ease often causes the child significant distress which may result in their inability to fully participate in classroom and recreational activities. Children with hemianopsia may search their blind field with their intact vision, but this search may be slow. Slow search patterns do not allow comprehension of the environment fast enough to avoid an obstacle.

Homonymous hemianopsia and reading challenges

Reading can present a particular challenge to a child with homonymous hemianopsia. Mean reading speed can be diminished, resulting in subjectively diminished reading performance: in other words, because the child cannot read as fast as their typically-developing peers, they and their educators believe they do not read well.

Right hemianopsia, which results after left hemispherectomy, can have a severe impact on reading in individuals who read languages that are written and read from left to right (e.g. English, Spanish, French) as one is always reading into the blind spot.

VISION

Left hemianopsia, which results after right hemispherectomy, can also have a significant impact on reading. Children may have problems finding the subsequent line of text. Also, because the first part of a word often contains information to quickly identify it, they may have frequent reading errors.

Hemispatial neglect and vision

Many children after hemispherectomy have hemispatial neglect - the inability to recognize stimulus coming from their affected side. People with hemispatial neglect are often unaware of their condition. Friends or therapists might suggest they look to their neglected side but that instruction misunderstands the problem they have with navigating the space around them: because the child is completely unaware that something is missing from their affected side in the first place, it is extremely difficult for them to be aware of it even after prompting.

Visual processing

Visual processing, or the brain's ability to understand and process what the eyes see, can sometimes be a challenge after hemispherectomy. Due to the nature of the surgery, the connections of the occipital lobe (the part of the brain that receives input from the eyes) is disconnected from other parts of the brain which may result in visual processing difficulties.

Visual processing is comprised of several different parts and includes:

1. visual closure - knowing what an object is when seeing only part of it. A child with visual closure issues may struggle to identify a word when they can only see a few letters (as may occur due to homonymous hemianopsia);
 2. visual discrimination - using eyesight to compare features, like color and shape, from one to another object. A child with visual discrimination issues may confuse one letter for another;
 3. visual figure-ground discrimination - differentiating a shape or word from its background. A child with visual figure-ground discrimination may struggle to pick out numbers or words from a page;
 4. visual memory - recalling something the child saw recently. A child with visual memory problems may struggle to recall a written phone number or how a word is spelled;
 5. visual sequencing - distinguishing the order of numbers, letters, words, or images. Problems with visual sequencing may cause a child to struggle with filling in the bubbles on a test, aligning numbers for addition or subtraction, or keeping their place when reading a page;
 6. visual-spatial processing - understanding how an object's location relates to you. A child with visual-spatial processing issues may struggle with judging time, reading a map, etc.;
 7. visual-motor processing - using the eyes to coordinate body movements. Children with visual-motor processing may be unable to copy word or judge the distance of an object.
-

Other visual challenges

Other visual challenges such as strabismus ("lazy eye"), cortical vision impairment, nystagmus, and depth perception may occur either because of the procedure or due to the underlying brain condition that caused the seizures in the first place.

MOBILITY

Hemiparesis

Because the surgery removes or disconnects the upper motor neurons from one side of the brain that are responsible for approximately 90% of intentional movement on the opposite side of the body, the child is left with hemiparesis - a severe weakness of the opposite side of the body. Existing connections to the motor neurons of the remaining part of the brain, however, make it possible for the child to recover some movement, including the ability to walk and use the affected hand as an assist or for some bimanual activities. Although fine motor of the hand will be impaired greatly, the child should be able to move their shoulder, upper arm, and sometimes wrist. Some finger movement, especially closing of the hands, can occur after therapy.

Children with hemiparesis often have difficulty maintaining their balance due to weakness. Performing daily living tasks such as dressing, eating, grabbing objects, or using the bathroom can be difficult. Most children require orthotic devices for their feet to address drop foot, ankle weakness, pronation, and other issues.

Coordination

Some children may have poor psycho-motor coordination, which is often manifested in clumsiness and a general unawareness of the space their bodies occupy.

Hemispatial neglect and vision

Hemispatial neglect after hemispherectomy can include motor deficits. A child with motor neglect may not use their affected limb despite the ability to do so.

Spasticity and tightness

Because the upper motor neurons of the brain are removed on the diseased side, many children eventually develop spasticity and tightness of the hand, arm, foot, and ankle. This is commonly referred to as upper motor neuron syndrome. Physical and occupational therapists should be aware of this challenge for a child after hemispherectomy, and provide adequate interventions and splinting as appropriate.

Hip and shoulder subluxation

Children with hemiparesis sometimes develop hip and/or shoulder subluxation - where the ball of the main joint migrates out of the socket. This can cause pain and, in cases of complete subluxation, inability to walk or move the arm. Leg length discrepancy is one sign of hip subluxation, and significant shoulder sag (where clothing slips off the shoulder) is a sign of shoulder subluxation. Occupational and physical therapists working with children in the educational environment after hemispherectomy should be aware of this potential issue and report any change in gait or arm movement to the parent.

FINE MOTOR

Hemiparesis

As discussed above, hemispherectomy has a profound effect on the child's ability to use the hand opposite the removed hemisphere. Isolating finger movement, turning the hand over (palm up), and holding the wrist at a proper angle is extremely difficult, as is grasping and releasing objects.

Some children after hemispherectomy do better switching to one-handed typing or dictation if the struggle of handwriting becomes too daunting.

Additionally, fine motor control in the unaffected hand can be impaired because the motor neurons that were once responsible only for innervating the unaffected hand are now required to innervate both hands. This can cause poor handwriting or other fine motor challenges.

Frequent physical or occupational therapy is required to help develop these skills. Such therapy is most effective when it is initiated at an early age and may be needed throughout the educational experience.

Bimanual tasks should be encouraged in therapy sessions. These include activities that require using the affected hand as a stabilizer, an active/passive assist, or manipulator. Card games, arts and crafts, and other activities can be incorporated into therapy sessions to develop bimanual tasks.

SENSORY

The sensorimotor strip in the brain is responsible for relaying the sensation of touch throughout the body, as well as proprioception (the ability to sense your body's position in space) and kinesthesia (ability to sense your body moving in space.) Because the procedure removes or disconnects the sensory strip on one side of the brain, sensation, proprioception, and kinesthesia can be profoundly affected. This may include aversity to certain food tastes or textures, sensory-seeking behaviors such as biting/chewing on toys or pencils, or similar behavior. In some children, sensory processing disorder may be diagnosed. Appropriate therapy interventions should be commenced to address sensory challenges as soon as possible.

.....

Sensory Processing Disorder

Our senses help us understand the world around us. They include sight, taste, smell, sound, touch, proprioception (sensing where one's body is in space), and balance. Sensory input from the environment is processed by the brain by its elaborate connections; however, when parts of the brain are removed and disconnected from the other as in hemispherectomy surgery, sensory processing disorder may arise.

Children with sensory processing disorder may over-respond to sensation and, for example, find clothing uncomfortable. Anecdotally, some parents report that after hemispherectomy their child may over-react to light, sound, certain food or play item textures (e.g. Play Doh or shaving cream), and find them unbearable. Difficulties with proprioception and vestibular/balance are also a common complaint.

Educational professionals should be aware of all sensory input which may affect the child's ability to succeed in an educational environment. Children with sensory processing disorder may benefit from a treatment program of occupational therapy with a sensory integration approach. Interventions may include listening therapy (e.g. Integrated Listening Systems) and other therapies.

HEARING

Challenges with hearing after hemispherectomy are poorly understood. Most children will pass a typical pure tone hearing test (given while the child is wearing ear phones so that information can be assessed for each ear) because the remaining hemisphere of the brain can assess the single tone given separately in each year during the test; however, when the single hemisphere is required to process sounds coming into both ears at the same time, problems arise. Many children struggle with central auditory processing disorder, hyperacusis, or misophonia.

Central auditory processing disorder

Central auditory processing disorder is a condition where the brain is unable to process incoming words or sounds properly. A child with central auditory processing disorder may be easily distracted or unusually bothered by loud or sudden noises, gets upset in noisy environments, has difficulty following directions, struggles with abstract information such as math word problems, or has difficulty following conversations.

Research shows that children after hemispherectomy will do well on “sound in quiet” tests (where they listen to different environmental sounds and words, without ear phones, in a sound-proof booth); however, when there is competing noise from the environment (“sound in noise”) or environmental sounds or words coming into both ears at the same time (“dichotic listening”) hearing is impaired. Regardless of right v. left hemispherectomy, recognizing words in noise is impaired. In addition, after left hemispherectomy, recognizing filtered words (distorting the word sounds) is often impaired as well.

This presents a serious problem for children after hemispherectomy in an educational environment. A child may be trying to listen to curriculum instruction from the teacher while a classmate is talking behind him. He may be trying to follow a speech therapist’s intervention during a group speech session with other children making noise in the room. This process is often challenging, even for persons with normal hearing and cognitive abilities; but, for a child with physical, visual, and cognitive challenges, this can be overwhelming.

Because a child after hemispherectomy typically has good auditory recognition of spoken words in a quiet environment, a quiet educational environment may be needed during times of academic instruction.

Hyperacusis

Anecdotally, many parents report that their child is hyper-sensitive to loud noises such as dogs barking, fire engine sirens, and books slamming onto the floor.

Misophonia

Although case reports are absent in the research literature, anecdotal reports from parents establish that many children are hypersensitive to certain common environmental sounds after hemispherectomy surgery. Sounds of rustling papers, squeaky doors, or the hum of an air conditioner may be problematic for the remaining half of the brain to process, causing the child distress.

LEARNING AND INTELLECTUAL DISABILITIES

Research studies, although limited, show that the average intellectual quotient (IQ) of a child after hemispherectomy is typically in the 70s, with some achieving normal IQ of 85 or higher, and others at 50 or below; however, it is now known that IQ test scores account for only 40- 50% of expected achievement in the general population of people with intellectual disabilities. With intensive intervention, children after hemispherectomy with intellectual and/or learning disabilities can be successful in school.

Children after hemispherectomy are likely to have learning disabilities in specific information processing areas, such as difficulties understanding complex and abstract concepts, difficulties in retrieving stored information, and spatial/perceptual disorders. As they grow older, it is possible that they may make slow progress in certain language skills compared to their peers. Problems in these areas may emerge in the late-elementary and middle school grades.

Reading

Reading is the most significant issue affecting the life of a child after hemispherectomy. Only 42% over the age of 6 years old have satisfactory reading skills. In typically-developing children, the left hemisphere of the brain is well known to support crucial aspects of language such as phonemic awareness (understanding the relationship between letters and sounds), syntax (arranging words and phrases to form sentences), morphology (the grammatical units of a language, such as, in English, the rule that the letter s at the end of a word makes it plural), as well as language meaning. The right hemisphere is traditionally dedicated to language in context, such as pragmatics (such as knowing when to take turns in conversation), prosody (speed patterns and stresses in a language), and meaning. When one side is removed, reading challenges ranging from problems with phonological processing to serious reading comprehension issues can arise.

Because it is well-settled that children with mild-to-moderate intellectual disability can learn to read given consistent, explicit, and comprehensive reading instruction across an extended period of time - at least three years or more - it is imperative for children to have intense instruction after hemispherectomy. Because of the severe nature of the surgery and the history of intractable epilepsy, regardless of which side of the brain was removed, *all children post-hemispherectomy should be considered with or at risk for reading disabilities*. Identification of a child at risk for reading disability should be done **in preschool**.

Phonics

Phonics is one of the primary building blocks of reading. Without an understanding of the relationships between letters and sounds (phonemic awareness), reading cannot occur. Phonemic awareness has been shown to predict reading levels both in average readers as well as readers with cognitive impairments.

In typically-developing children, phonemic awareness is a function of the left hemisphere of the brain. Therefore, after left hemispherectomy, the phonemic route can be severely impaired making it difficult for the child to understand the rules of phonics. Children after left hemispherectomy may struggle with decoding (reading nonwords), phonological memory (temporarily storing new phonological information in working memory), and paragraph comprehension. Multi-modal reading interventions, including whole word learning, should be considered for the child struggling with phonics.

LEARNING AND INTELLECTUAL DISABILITIES

Comprehension

Typically-developing children are expected to apply the reading skills they have learned to new, more challenging content by 4th grade: once they have learned to read, they must read to learn. After hemispherectomy, reading comprehension can be challenging for a child regardless of side of surgery. For this reason, multi-modal methods of teaching reading comprehension must be utilized.

Reading aloud

Educators are cautioned to draw conclusions regarding a child's reading ability based on their prosody (timing, phrasing, emphasis, and intonation) or rapid automatized naming (how quickly the child can name an object aloud.) Issues in this area may be related to the child's visual deficits, motor planning struggles, or hemiparesis of muscles in the mouth (dysarthria).

Nonverbal learning disorder

Significant disparities between verbal intelligence and non-verbal intelligence in neuropsychological evaluations are reported in research studies and data collected to date after hemispherectomy. Anecdotally, parents of verbal children after hemispherectomy report their child speaks well in social and academic environments but has been diagnosed with a nonverbal learning disorder (NLD.) Children with NLD do not accurately process information that is not verbal or linguistic in nature. Instead, they rely almost exclusively on a very literal interpretation of verbal communication. Their ability to organize the visual-spatial field, adapt to new or novel situations and/or accurately read nonverbal signals and clues (such as body language) is impaired.

NLD encompasses three areas: motor (lack of coordination, balance problems and difficulties with fine grapho-motor skills); visual-spatial-organizational (poor visual recall, faulty spatial perceptions, difficulties with spatial relations); and social (inability to comprehend nonverbal communication, difficulties adjusting to novel situations and deficits in social judgment and interaction.) Some characteristics of NLD are similar to, and often misdiagnosed as, attention deficit hyperactivity disorder (ADHD).

Organizational skills

The child after hemispherectomy may have problems with organizational skills. They may have difficulty following multi-step instructions and often have trouble integrating and interpreting incoming information. They may pay attention to each detail as it comes in, rather than combining them into more meaningful wholes.

SPEECH AND LANGUAGE

In approximately 95% of typically-developing children, speech and language is a function of the left hemisphere of the brain; however, after left hemispherectomy surgery, approximately 44 - 76% of children have expressive and receptive language skills depending on the underlying condition which caused the seizures. Some are even bilingual. Thus, educators, evaluators, and therapists are **strongly cautioned** against drawing any conclusions about the ability to speak based upon the side of surgery.

Regardless of the primary deficit, children with severe speech impairment need intensive speech therapy as *early as possible*. Young children benefit from frequent shorter sessions (e.g., up to four times/week for 30 minutes each session). These are preferable over longer, less frequent sessions.

Expressive verbal speech

Expressive speech can be challenging after hemispherectomy. Children who spoke prior to the surgery may take several years to fully return to baseline. Additionally, children who did not speak prior to hemispherectomy have been known to speak afterwards, even when surgery occurred as late as nine years old.

Apraxia

Because the surgery removes parts of the brain responsible for motor planning and intentional movement, many children after hemispherectomy are diagnosed with apraxia. Apraxia is a motor speech disorder where the child has problems saying sounds, syllables, and words; the child knows what he/she wants to say, but the brain has difficulty the muscle movements necessary to say it.

It is well-settled in the research literature that children with apraxia require intensive therapy services. Therapy should be provided individually.

Dysarthria, articulation, and prosody

Many children have challenges with articulation (making clear speech sounds) and prosody (patterns of stress and intonation) which may be caused by motor planning challenges or motor deficits related to hemiplegia, and which can also affect the oral muscles used in speech. Mild dysarthria is common after hemispherectomy, leading to issues with intelligibility and audibility of vocal communication; thus, appropriate therapy interventions to help with articulation should be instituted early.

ASSISTIVE COMMUNICATION DEVICES

Augmentative and alternative communication (AAC) includes all forms of communication (other than oral speech) that are used to express thoughts, needs, wants, and ideas. People with severe speech or language challenges rely on AAC to supplement existing speech or replace speech that is not functional. Special augmentative aids, such as picture and symbol communication boards and electronic devices, are available to help people express themselves. This may increase social interaction, school performance, and feelings of self worth.

AAC users should not stop using speech if they are able to do so. The AAC aids and devices are used to enhance their communication. The following AAC techniques and devices should be considered for the non-verbal or limited-verbal child after hemispherectomy:

- Picture exchange communication system;
- Big Mac Button;
- iPad applications, such as Yes/No HD, TouchChat, etc.

BEHAVIOR

Significant behavioral problems have been reported in approximately 27% of children after hemispherectomy. Challenging behaviors can include:

- Inattention;
- Impulsivity;
- Attention Deficit Hyperactivity Disorder (ADHD);
- Autism/Autistic characteristics (hand flapping, humming, perseveration, self-stimulation);
- Hyperkinesia (inability to sit still);
- Impaired socialization.

Autism spectrum disorder (ASD) and attention deficit hyperactivity disorder (ADHD) are the two most common neuropsychiatric disorders in children with epilepsy, especially if the epilepsy is resistant to medication (a prerequisite for any child being considered for hemispherectomy surgery.) Behavioral intervention strategies, especially applied behavior analysis, should be strongly considered by the educational team as a service for a child after hemispherectomy surgery.

Socialization

The ability to successfully attribute mental states to other people and understand them as a cause of behavior is a key process in guiding a variety of social behaviors and activities. Impairments in the ability to read social situations can contribute to social separation or isolation from the child's peer group or impact their ability to find employment and sustain friendships in adulthood.

BEHAVIOR

Challenges after hemispherectomy may include, but are not limited to:

- problems identifying when a speaker is lying or sarcastic exchanges;
- difficulty recognizing negative facial emotions such as anger, fear, disgust, or sadness;
- expressions of love and affection that are socially inappropriate given the context of the situation.

Behaviors and anti-epileptic medications

Because hemispherectomy surgery has only a 50 - 85% success rate, many children remain on anti-epileptic drugs (AEDs) after the procedure. AEDs may cause behavioral challenges; therefore, educators should be aware of the drugs taken by the child and their effects.

EMOTIONAL CHALLENGES

Medical trauma and post-traumatic stress disorder

The post-hemispherectomy child has likely undergone many traumatic medical experiences at a young age, including countless seizures, medical and surgical procedures, and never-ending doctor visits. Although medical trauma does not rise to the level of post-traumatic stress disorder in every child, the educational team should be well-informed of these experiences and how they may affect the child in the educational environment.

Research shows that students who have experienced a traumatic event are at increased risk for academic, social, and emotional problems as a result of these experiences. Schools can be an ideal setting for mental health professionals to intervene with traumatized students, by supporting both their trauma-related psychological problems and their ability to learn in the classroom.

Social isolation and educational progress

Children with physical disabilities are already aware of their difference from other children and can feel socially isolated and rejected. Sometimes, due to specific learning disabilities, they have been unable to develop age-appropriate social skills. Social isolation and frustration about not fitting in or feeling different can lead to emotional problems.

Some children may have a constellation of issues including ADHD, a learning disability, physical challenges, and emotional and/or behavioral problems. If the child's mental health disability results in difficulty making and keeping friends, isolation from peers, or frequent altercation with peers, then the disability interferes with the child's ability to take advantage of the instruction that is provided by the school.

Educational progress is more than just academic progress. Social skills development is part of the educational process. If the child's disability is serious enough to warrant special mental health and therapeutic interventions, these should be provided to enable him to make friends and socialize appropriately. In this case, the educational team should request an assessment for educationally-related mental health services (ERMHS Evaluation).

Educationally-related mental health services can include outpatient mental health counseling, family therapy, parent counseling and training, day treatment, therapeutic services provided at a nonpublic school, and coordinated, case-managed mental health service provided by a therapeutic team, sometimes called wraparound services.

OTHER CONSIDERATIONS

Headaches and migraines

Headaches after hemispherectomy are common, and some can mimic migraines; however, headaches can also be a symptom of hydrocephalus or shunt malfunction. Parents should be advised immediately if headaches are reported as more frequent or severe by the child.

.....

Fatigue

At least 75% of persons with brain injury report fatigue. Educational instruction should be provided at times when the child is the least fatigued.

.....

Seizures

Not all children are seizure-free after hemispherectomy surgery. Although hemispherectomy surgery has the highest rate of seizure control of all the epilepsy surgeries (with 60 - 85% of children seizure-free depending on the underlying cause of the seizures) return of seizures post-surgically can present serious challenges in the educational environment.

A seizure plan is a must for any child after hemispherectomy surgery, regardless of whether they are seizure-free at the time of the educational meeting. All members of the child's educational team should be trained in identifying seizures. Although the scope of this guide does not include an in-depth discussion of types of seizures and their presentation, a brief review is appropriate here:

- A seizure can be anything from something as simple as feeling a déjà vu, a "staring spell," a stomach ache, to a convulsion that includes dropping to the floor, uncontrollable shaking, and loss of consciousness;
 - Loss of consciousness does not define a seizure. A child can be completely aware during a seizure, hold a conversation, and even go about their activities;
 - Some seizures cannot be seen (subclinical seizures) but they often manifest themselves as changes in behavior, headaches, stomach pain, or photosensitivity. Parents should be advised immediately of any abrupt or unusual change in behavior.
-

Hydrocephalus

At any given time, the brain is bathed by approximately a half a cup of cerebrospinal fluid. If too much cerebrospinal fluid is present in the brain, it can cause a serious increase in intracranial pressure that can lead to permanent brain damage, coma, and in extremely rare cases, even death. (Conversely, too little cerebrospinal fluid can lead to similar problems. Children who have shunts post-hemispherectomy can over-drain, causing similar issues.)

Approximately 23% of children develop hydrocephalus after hemispherectomy surgery, some up to ten or more years later. The educational team should be familiar with the symptoms of hydrocephalus and report them to the parent immediately. They include, but are not limited to:

- | | |
|------------------------------------|-----------------------|
| Seizures; | Vomiting; |
| Dizziness; | Problems with vision; |
| Problems with balance or mobility; | Behavioral changes. |
| Sleepiness; | |

If the child has a shunt, and exhibits any of the symptoms listed above, they may be experiencing shunt failure.



The Brain Recovery Project

BELIEVE IN THE OTHER HALF

107 S. Fair Oaks Avenue, Suite 315, Pasadena, CA 91105

P: 626-225-2841 • **F:** 626-708-0237 • brainrecoveryproject.org

©TheBrainRecoveryProject

For additional information about hemispherectomy, including fact sheets for educators, infographics, and recommendations for assessments, aids, and services, visit our website.

THIS GUIDE IS ADAPTED FROM:

Assessments, Evaluations, Tests. Wrights Law website. <http://www.wrightslaw.com/info/test.index.htm>. Updated 03/18/15. Accessed May 7, 2015.

Augmentative and Alternative Communication. The American Speech-Language-Hearing Association website. <http://www.asha.org/public/speech/disorders/AAC/>. Accessed May 7, 2015.

Berg AT, Caplan R, Hesdorffer DC. Psychiatric and neurodevelopmental disorders in childhood-onset epilepsy. *Epilepsy & Behavior*. 2011; 20(3):550-555.

Bundy AC, Shia S, Qi L, Miller LJ. How does sensory processing dysfunction affect play? *American Journal of Occupational Therapy*. 2007; 61, 201–208.

de Bode, S, Chanturidze, M, Mathern, GW, Dubinsky, S. Literacy after cerebral hemispherectomy: Can the right hemisphere read? *Epilepsy & Behavior*. 2015.45:248-253.

de Bode, Stella, Ph.D. "Synthesis of Reading Research." Talk presented at: 2014 International Hemispherectomy Conference and Family Reunion. California, Anaheim. 12 July 2014.

de Bode S, Slinger Y, Healy EW, Mathern GW, Zaidel E. Dichotic listening after cerebral hemispherectomy: methodological and theoretical observations. *Neuropsychologia*. 2007;45(11):2461-2466. doi:10.1016/j.neuropsychologia.2007.03.026.

Bouchard KE, Mesgarani N, Johnson K, Chang EF. Functional organization of human sensorimotor cortex for speech articulation. *Nature*. 2013; 495(7441):327-332.

Connor CM, Alberto PA, Compton DL, O'Connor RE (2014). Improving reading outcomes for students with or at risk for reading disabilities: A synthesis of the contributions from the Institute of Education Sciences Research Centers (NCSE 2014-3000). Washington, DC: National Center for Special Education Research website. <http://ies.ed.gov/ncser/pubs/20143000/>

Curtiss, S, de Bode, S, Mathern, GW. Spoken language outcomes after hemispherectomy: factoring in etiology. *Brain and Language*. 2001; 79(3):379-96.

Feldman J, Rosenbaum S. Special Education Rights and Responsibilities Handbook, Community Alliance for Special Education website. <http://www.caseadvocacy.org/handbook.html>. 2011. Accessed May 7, 2015.

Flexman AM, Ng JL, Gelb A W. Acute and chronic pain following craniotomy. *Current Opinion in Anaesthesiology*. 2010; 23 (5): 551–557.

Fournier NM, Calverley KL, Wagner JP, Pooch JL, Crossley M. Impaired social cognition 30 years after hemispherectomy for intractable epilepsy: The importance of the right hemisphere in complex social functioning. *Epilepsy & Behavior*. 2008; 12(3), 460-471.

Gagner C, Landry-Roy C, Lainé F, & Beauchamp MH. (2015). Sleep-wake disturbances and fatigue following pediatric traumatic brain injury: a systematic review of the literature. *Journal of neurotrauma*. 2015 Apr 19.

Goodwin D. Homonymous hemianopia: challenges and solutions. *Clinical Ophthalmology (Auckland, NZ)*. 2014; 8:1919-1927.

Lew SM, Koop JI, Mueller WM, Matthews AE, Mallonee JC. Fifty consecutive hemispherectomies: outcomes, evolution of technique, complications, and lessons learned. *Neurosurgery*. 2014;74(2):182-195.

Hydrocephalus Association. A Teacher's Guide to Hydrocephalus. http://www.hydroassoc.org/docs/A_Teachers_Guide_to_Hydrocephalus.pdf. Published 2002. Accessed June 3, 2015.

Hydrocephalus Association. About Hydrocephalus—A Book for Families. Published by the University of California, San Francisco, 1986. http://www.hydroassoc.org/docs/About_Hydrocephalus_A_Book_For_Families1.pdf. Accessed June 3, 2015.

Liegeois, F, Morgan, AT, Stewart, LH, et al. Speech and oral motor profile after childhood hemispherectomy. *Brain and Language*. 2010 Aug; 114(2):126-134.

Kataoka S, Langley A, Wong M, Baweja S, Stein B. Responding to Students with PTSD in Schools. *Child and Adolescent Psychiatric Clinics of North America*. 2012;21(1):119.

Little L. The misunderstood child: the child with a nonverbal learning disorder. *Journal of the Society of Pediatric Nurses*. 1999; 4 (3) 113-21.

McGrew KS, Evans J. (2004). Expectations for students with cognitive disabilities: Is the cup half empty or half full? Can the cup flow over? (Synthesis Report 55). Minneapolis, MN: University of Minnesota, National Center on Educational Outcomes. <http://education.umn.edu/NCEO/OnlinePubs/Synthesis55.html>. Accessed June 5, 2015.

Moosa AN, Jehi L, Marshly A, et al. Long-term functional outcomes and their predictors after hemispherectomy in 115 children. *Epilepsia*. 2013 Oct; 54(10):1771-9.

Owen JP, Marco EJ, Desai S, et al. Abnormal white matter microstructure in children with sensory processing disorders. *NeuroImage : Clinical*. 2013; 2:844-853.

Paiement, P, Champoux, F, Bacon, BA, et al. Functional reorganization of the human auditory pathways following hemispherectomy: an fMRI demonstration. *Neuropsychologia*. 2008 Oct;46(12):2936-42. doi: 10.1016/j.neuropsychologia.2008.06.009.

Recommended Special Education Programs and Services. New York State Education Department website. <http://www.p12.nysed.gov/specialed/publications/iepguidance/programs.htm>. Updated December 2012. Accessed May 7, 2015.

Ross Nagy E. Management of the hemiplegic shoulder. The American Association of Occupational Therapy website. <http://www.aota.org/-/media/Corporate/Files/ConferenceDocs/Conclave/2013SCSchedule/2013%20handouts/HandoutConcurrent13.pdf>. 2013. Accessed June 3, 2015.

Sankar, Raman S. "Seizure Medications After Hemispherectomy." Talk presented at: 2011 International Hemispherectomy Conference and Family Reunion. California, Anaheim. 9 July 2011 [video] <https://www.youtube.com/watch?v=ApJEZj4EHfo>. Published January 11, 2013. Accessed June 4, 2015.

Silaanpaa M, Cross H. The psychosocial impact of epilepsy in childhood. *Epilepsy & Behavior*. 2009 Jun; 15 Suppl 1:S5-10.

State and District-Wide Assessments and Students with Learning Disabilities: A Guide for States and School Districts. LD Online website. <http://www.ldonline.org/educators/strategies/assessment>. 2004. Accessed May 7, 2015.

Swan, L. Unilateral spatial neglect, *Physical Therapy*. 2001; 81(9), 1572-1580.

Thompson S. Nonverbal learning disorders. Nonverbal Learning Disorders on the Web website. <http://www.nldontheweb.org/nldadvancedreading/nld.html>. Published 1995. Accessed June 3, 2015.

Turkel S, Pao M. Late consequences of pediatric chronic illness. *The Psychiatric clinics of North America*. 2007; 30(4):819-835.

Vargha-Khadem, F, Carr, LJ, Isaacs, E, Brett, E, Adams, C, Mishkin, M. Onset of speech after left hemispherectomy in a nine-year-old boy. *Brain*. 1997; 120, 159–182

Vydrova R, Kršek P, Kyncl M, Jahodova A, Dvorak J, Komarek V, Delalande O, Tichy M. Peri-ictal headache due to epileptiform activity in a disconnected hemisphere. *Epileptic Disorders*. 2014;16(2):213-217.